

Bioabsorbable versus Metallic Screw Fixation of Distal Tibiofibular Syndesmosis Injuries

by Timothy J. Levar DPM¹, James C. Connors DPM², Mark A. Hardy DPM, FACFAS³

The Northern Ohio Foot and Ankle Journal 1 (6): 1-6

Abstract: Rotational ankle fractures or dislocations often cause traumatic tearing of the tibiofibular syndesmotoc ligament. Unstable ankle injuries require fixation of the syndesmotoc ligament to restore normal function and anatomical alignment. The syndesmosis is a dynamic structure that allows the ankle joint to accommodate the natural motion of the talus within the mortise. When the syndesmosis is disrupted the talus may displace laterally causing altered biomechanics of the ankle joint. The tibiofibular syndesmotoc ligament must have the normal physiological tension restored to prevent this talar displacement within the ankle. Rigid fixation is still considered the standard treatment especially for higher risk patients. Metal screw fixation allows stable healing of the syndesmosis by reducing any diastasis at the joint. During the postoperative period, the recommencement of normal weight bearing can cause metallic screw failure and subsequent removal. Successive screw extraction carries added risk and financial cost. Routine removal may even lead to recurrent diastasis of the syndesmosis. The use of bioabsorbable screw affords the patient the stability of solid fixation without the need for an additional removal procedure. This retrospective review demonstrates that absorbable screw fixation permits early weightbearing of less than half of the standard of care with metallic screws without radiographic evidence of diastasis.

Key words: ankle fracture, bioabsorbable screw, syndesmotoc injury

Accepted: June, 2015 **Published:** June, 2015

This is an Open Access article distributed under the terms of the Creative Commons Attribution License. It permits unrestricted use, distribution, and reproduction in any medium, provided the original work is properly cited. ©The Northern Ohio Foot and Ankle Foundation Journal. (www.nofafoundation.org) 2014. All rights reserved.

Ankle fractures are some of the most common types of fractures, reported 18% of skeletal injuries annually [1]. Approximately 1 in 7 ankle fractures has concurrent damage to the distal tibiofibular syndesmotoc [2]. Mueller et al. found that the fibula moves proximally and distally to maintain normal biomechanics of the ankle joint [3]. The syndesmotoc ligament allows for axial motion between the fibula and tibia while also providing some external rotation [4]. Failure to diagnose and treat these disruptions has been shown to have poor long term

outcomes. Numerous techniques have been described for operative reduction of the syndesmosis. The ideal method to stabilize the syndesmosis should be strong enough to resist diastasis and permit early mobilization while allowing physiologic micromotion [5]. Metallic screw fixation is considered the current gold standard in treatment of these injuries [4]. However, removal of these retained screws is sometimes necessary and may improve functional outcomes [1]. The retained screw may cause painful irritation and limit dorsiflexion [2].

Typically, the patient is ordered to be nonweightbearing from 8 to 12 weeks or until the screw is removed or fails [5]. Metal screws are typically inserted quadricortically to allow for easy retrieval if broken, which has been shown to require more

Address correspondence to: connorsjc2@gmail.com Resident, Department of Foot and Ankle Surgery, Mercy Health Physicians

1. Private practice, Willoughby Foot & Ankle Specialist, Willoughby OH

2. Podiatric Medicine and Surgery Resident, Mercy Health, Cleveland OH

3. Director of podiatric surgical residency, Mercy Health. Department of Foot and Ankle Surgery, HealthSpan Physicians Group, Cleveland, OH.

frequent future removal [6]. Bioabsorbable fixation offers several advantages over metallic screw fixation in these types of injuries. Bioabsorbable screws are hydrolyzed and resorbed, thus eliminating the need for removal. Also, these implants permit gradual transfer of stress to the bone resulting in improved remodeling and healing [7]. The purpose of our retrospective comparative study is to compare the outcomes and assess the efficacy of bioabsorbable screw fixation versus metallic screw fixation of acute injuries to the distal tibiofibular syndesmosis.

Materials and Methods

Between September, 2006 and October, 2011, 21 adult patients with external rotation type injuries and intra-operative confirmation of disruption of the distal tibiofibular syndesmosis were retrospectively reviewed. Included in this study was any closed, unstable, trimalleolar, bimalleolar, lateral malleolar, or Maisonnueve fracture undergoing ORIF by one surgeon (Fig. 1).

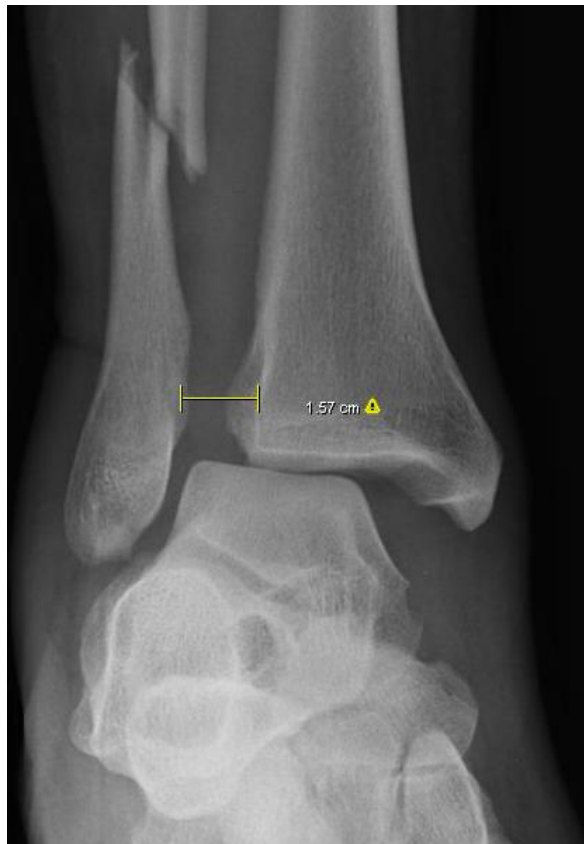

Fig. 1 Preoperative measurement of tibiofibular diastasis indicating syndesmosis disruption.

In these patients, the syndesmosis was reduced with either metallic (group 1, n=11) (Fully threaded cortical stainless steel 3.5mm or 4.5mm screw) or bioabsorbable (group 2, n=10) (Arthrex® Trim-It™ Screw System, 100% PLLA, 3.5 or 4.5mm Fig. 2) fixation.

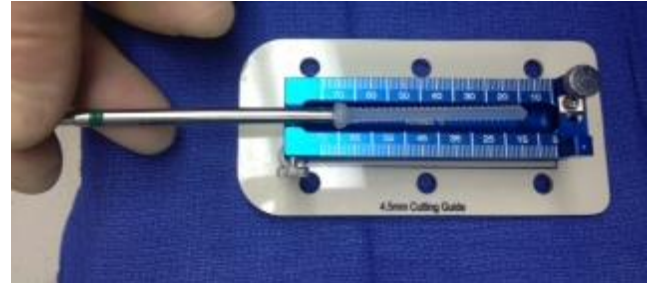


Fig. 2 PLLA syndesmosis screw

Clinical and radiographic follow-up was performed. Radiographic assessment included measurement of tibiofibular clear space 1 cm above tibial plafond on mortise view (Fig. 3,4). Patients requiring subsequent procedures for transsyndesmosis implant removal were also recorded.

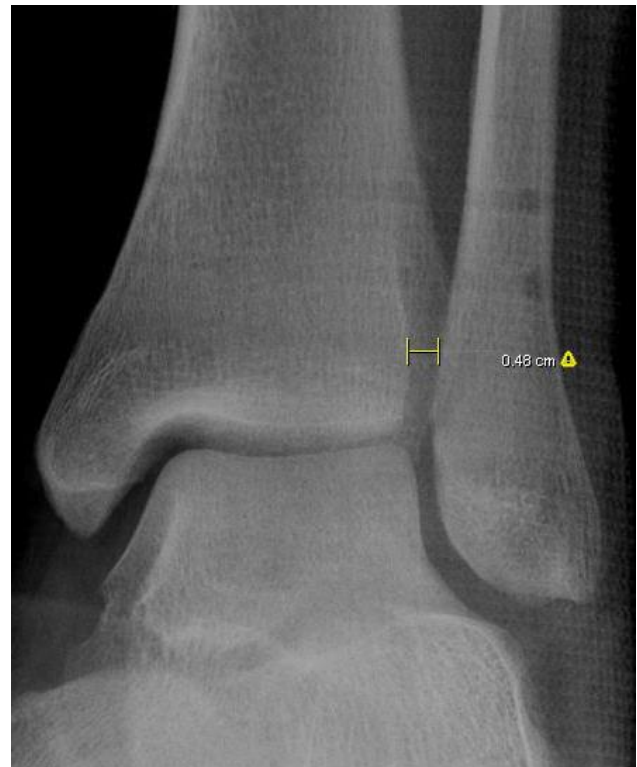

Fig.3 Tibiofibular clear space measurement after bioabsorbable screw fixation. Average radiographic follow 6.15 months for bioabsorbable screw fixation.

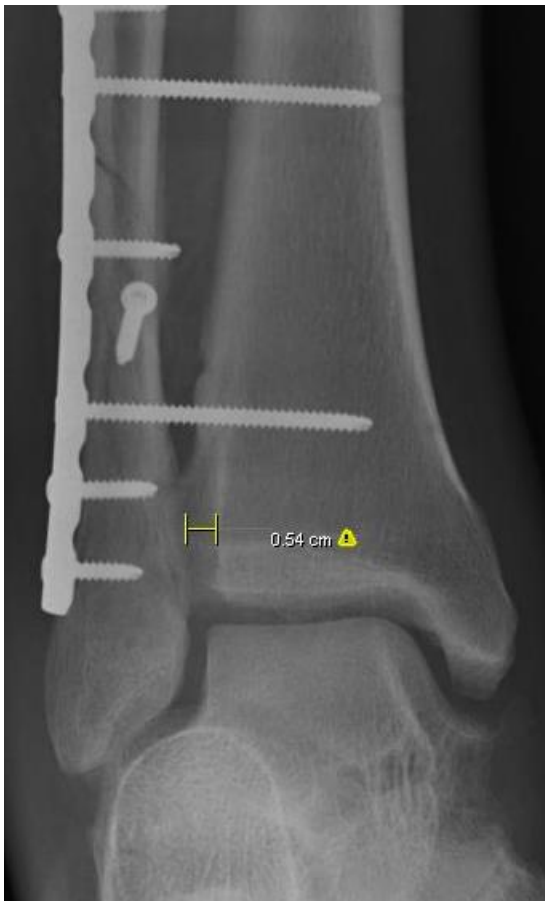

Fig.4 Tibiofibular clear space measure after metallic screw fixation.

After reduction of the fracture patterns, the syndesmosis was stressed with an external rotation force under live fluoroscopy. The syndesmosis was reduced using a large pelvic reduction clamp in both groups (Fig. 5). Either bioabsorbable or metallic screws were placed across the syndesmosis while purchasing 4 cortices using standard AO and manufacturer technique.

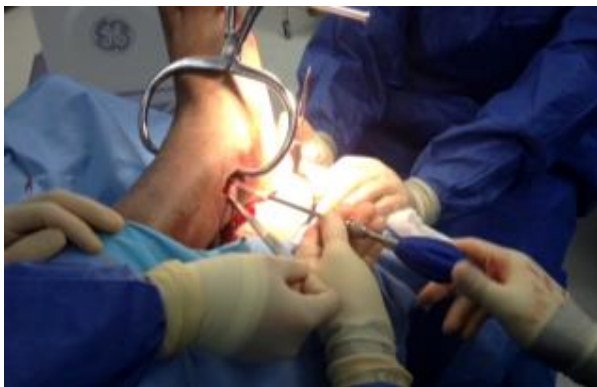

Fig. 5 Application of syndesmotoc clamp for reduction prior to screw insertion.

Results

Average age was 59.6, 40.9 years for groups 1 and 2 respectively. The average time to final radiographic examination and final clinical follow up was 8.7, 19.14 months (group 1) and 6.15, 12.15 months (group 2). The measurements of the tibiofibular clear space in both groups are represented in the table (Table 1).

Group 1 (cm)	Group 2 (cm)
0.31	0.51
0.38	0.48
0.34	0.42
0.43	0.52
0.51	0.41
0.39	0.34
0.35	0.40
0.62	0.41
0.32	0.32
0.42	0.37
0.43	N/A

Table 1. Patients were divided into two groups based on fixation. Tibiofibular clear space (cm) was measured postoperatively and no significant difference was found in this study population. The bioabsorbable screw fixation group returned to weightbearing in half of the recovery time.

The mean tibiofibular clear space for groups 1 and 2 was 0.41 and 0.42 respectively. Using an unpaired t test, the two-tailed P value=0.8185. This difference is considered to be not statistically significant between the groups. The 95% confidence interval ranged from -0.0871 to 0.0697. The most common construct was either two (metallic or bioabsorbable) 3.5mm or 4.5mm cortical screws. 2 patients (18.2%) in group 1 required a second procedure for screw removal. Both patients had complete resolution of their symptoms with screw removal. No patients in group 2 required hardware removal.

Discussion

Metal syndesmotic screw fixation frequently requires removal due to irritation and decreased motion at the ankle. The ensuing surgical removal increases the risk of postoperative complications [8]. All syndesmotic screws, metal or absorbable, have a potential to restrict normal motion or fail once full weight bearing is resumed.[9] Absorbable screws do not require future removal if failure occurs. Ahmad et al. showed that absorbable screws provided the strength required for full syndesmotic healing. The study demonstrated good to excellent results with 58 out of 70 patients [9].

In our preliminary study we have observed that bioabsorbable fixation of distal tibiofibular syndesmotic injuries is equally efficacious as metallic screw fixation. No statistical difference was observed for measurement of tibiofibular diastasis following surgery between the groups. In addition, the need for subsequent removal of the implant is virtually eliminated with the use of bioabsorbable fixation. There are weaknesses of this study including small patient population and low powered nature of the investigation. This is a preliminary study; we plan to assess functional outcomes of our patient population. In conclusion, bioabsorbable fixation of syndesmotic injuries is a viable alternative to the current standard metallic screw fixation. The use of bioabsorbable screws permitted weightbearing at less than half of the time without any evidence of radiographic diastasis. Absorbable screws possess more elasticity, which transmits more normal micromotion through the syndesmosis [5]. Bioabsorbable screws do not require removal and tricortical fixation technique may be utilized. This may further eliminate the need for screw extraction due to a reduction of irritation. Bioabsorbable screws have demonstrated the strength needed to prevent recurrent diastasis of the tibiofibular syndesmosis [9].

References

1. Miller AN, Omesh P, Boraiah S, et al. Functional outcomes after syndesmotic screw fixation and removal. *J Orthop Trauma*. 2010;24:12-16.
2. Schepers T. To retain or remove the syndesmotic screw: a review of the literature. *Arch Orthop Trauma Surg*. 2011;131:879-883.
3. Mueller, M.E., Allgower, M., Schneider, R., Willenegger, H.: *Manual of internal fixation – Techniques recommended by the AO Group*, 2nd Edition. Springer-Verlag, Berlin, 1979.
4. Thordarson DB, Samuelson M, Shepherd LE, Merkle PF, Lee J. Bioabsorbable Versus Stainless Steel Screw Fixation of the Syndesmosis in Pronation-Lateral Rotation Ankle Fractures: A Prospective Randomized Trial. *Foot Ankle Int* 2001;22: 335
5. van den Bekerom MPJ, Raven EEJ. Current concepts review: operative techniques for stabilizing the distal tibiofibular syndesmosis. *Foot Ankle Int*. 2007;28(12):1302-1308.
6. Hoiness P, Stromsoe K. Tricortical versus quadricortical syndesmosis fixation in ankle fractures: a prospective, randomized study comparing two methods of syndesmosis fixation. *J Orthop Trauma* 2004;18(6):331–337
7. Hovis WD, Kaiser BW, Watson JT, Bucholz RW. Treatment of syndesmotic disruptions of the ankle with bioabsorbable screw fixation. *J Bone Joint Surg*. 2002;84-A(1):26-31.
8. Schepers T, Van Lieshout EM, de Vries MR, Van der Elst M. Complications of syndesmotic screw removal. *Foot Ankle Int*. 2011;32(11):1040-1044.
9. Ahmad J, Raikin SM, Pour AE, Haytmanek C. Bioabsorbable Screw Fixation of the Syndesmosis in Unstable Ankle Injuries. *Foot Ankle Int* 2009;30: 99