

Tourniquet Use in the Lower Extremity

by Christopher Tulodziecki¹, DPM

The Northern Ohio Foot and Ankle Journal 1 (2): 6

The use of tourniquets in foot and ankle surgery is widely used and a mainstay in the operating room. Despite its long history and daily use, there remains no clear consensus in its application in hemostasis or prevention of complications. This review looks at the history, application, and complications of tourniquet use in the lower extremity.

Key words: tourniquet, exsanguination, esmarch

Accepted: June, 2015

Published: August, 2015

This is an Open Access article distributed under the terms of the Creative Commons Attribution License. It permits unrestricted use, distribution, and reproduction in any medium, provided the original work is properly cited. ©The Northern Ohio Foot and Ankle Foundation Journal. (www.nofafoundation.org) 2015. All rights reserved.

The tourniquet is routinely used in foot and ankle surgery for hemostasis. However, no clear consensus exists regarding exsanguination, limb protection, application, nor prevention of its complications. Fortunately, there are few complications that occur - most of which are preventable. Additionally, its contraindications are loosely stated and poorly defined in lower extremity literature. The purpose of this review is to explore current standards of protocol in order to optimize tourniquet application in foot and ankle procedures.

History

Tourniquet use dates back to 2nd century AD when Archigenes and Heliodorus in Rome used narrow bands of cloth placed directly above and below the line of incision, each passed two or three times about the limb and tied in a single knot. This application

mainly controlled venous bleeding rather than the sought after arterial hemostasis. There were little significant improvements over the course of the next 1500 years until Morell in 1674 used a stick to twist a constricting bandage [1].



Figure 1. Morell-type Tourniquet [1]

There were numerous modifications of the Morell-type tourniquet and although crude, it provided the basis of another greatly improved instrument. Jean Louis Petit, another Frenchman and the foremost surgeon in Paris during the first half of the eighteenth century, was the first to coin the term tourniquet and devised an instrument that did not require an assistant [2]. This tourniquet consisted of a strap wrapped

around the limb to which it was attached to a screw apparatus. Upon tightening, pressure is applied over the main vessel by the curved screw apparatus. The device was convenient in application and modifications of Petit's tourniquet appeared up through the late nineteenth century.




Figure 2. Petit-type Tourniquet [3]

Joseph Lister in the 1860s was the first surgeon to use the bloodless field for operations other than amputations. He emphasized elevation of the limb for 4 min before the tourniquet was applied based on experimental evidence and experience. He felt that there would be drainage of all venous blood in addition to arterial constriction.

Johann T. Friederich August von Esmarch is given credit for winding tensile material around a limb in order to express venous blood in combination with tourniquet. He was disturbed at the amount of blood still present in an amputated limb. However, he gave credit elsewhere for the bandage. The "Esmarch bandage" used today was actually designed by von Langenbeck who loosely based the bandage off previous designs by Esmarch. This elastic bandage is correctly termed "Langenbeck bandage."

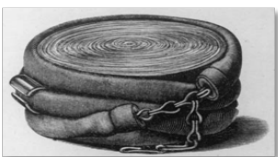

Figure 3. "Langenbeck" bandage [1]

Harvey Cushing introduced the pneumatic tourniquet to limb surgery in 1904. He abandoned the rubber tourniquet due to nerve palsy and difficulty in application. It originated off the recently invented Riva-Rocci blood-pressure apparatus in routine use in Italy. Today, the pneumatic tourniquet is a mainstay in the operating room and is routinely used in order to obtain a bloodless field with minimal complications.

Pathophysiology

Although tourniquet use is generally safe in the lower extremity with normal vascular supply, there are still effects that must be considered. There are systemic effects from inflation and deflation in addition to the local effects secondary to ischemia and direct mechanical pressure.

The cardiovascular effects can be pronounced upon tourniquet inflation. There is a shift in blood volume that causes an increase in systemic vascular resistance, which resulting in increased blood pressure. The reverse occurs during deflation with a further decrease in blood pressure beyond baseline due to the accumulation of metabolites during the ischemic period. Also during deflation, there is an increase in cardiac output along with hypercapnic venous blood returning to systemic circulation. The result, being an increase in end tidal carbon dioxide. In regards to hematological effects, there is a hypercoagulable state after inflation secondary to hemostasis; however, there is a decrease in coagulation after deflation due to tissue plasminogen activator release secondary to ischemic effects.

Metabolic effects occur primarily due to limb ischemia. Deflation of the tourniquet after one to two hours of inflation increases potassium and lactate in the limb. The pH decreases due to the increased lactate and carbon dioxide from the ischemic limb. Furthermore, there is some loss of temperature regulation during the inflation period; its been observed that there is a core temperature rise soon

after inflation due to the lost systematic circulatory heat loss.

Nerve injury may be seen; this can be a result of both ischemia and from direct pressure. The supra-systolic pressures cause conduction block. Nerve paralysis can result due to the direct pressure of the tourniquet cuff itself, especially straight cuffs. It is advised to use contoured and wide cuffs to reduce the chance of the patient undergoing nerve paralysis. Muscle injury can also occur secondary to progressive tissue hypoxia and hypercapnia. There is a risk of developing post-tourniquet syndrome as well. Post-tourniquet syndrome is characterized by edema, stiffness, pallor, weakness without paralysis, and subjective numbness without objective anesthesia; and, it is due to an increased vascular permeability leading to interstitial and intracellular edema. Sixty minutes can produce morphological changes in mitochondria and local fiber necrosis. Ischemia lasting longer than 2 hours can cause microvascular injury in the muscle. The above complications are rare and mostly preventable with adequate recognition.

Exsanguination and Limb Protection

There has been some degree of examination with the varying exsanguination methods. Esmarch exsanguination can be damaging to fragile or atrophic skin in the elderly and patients on chronic corticosteroids. It is contraindicated in infection, suspected malignancy, and soft tissue masses. It also may reduce shearing forces by placing gauze beneath the Esmarch.

Blond et al in 2002 compared exsanguination methods using elevation alone for thirty seconds at sixty degrees, Esmarch bandage, gauze bandage, and the Pomidor roll-cuff in healthy male patients [4]. Each of these methods were followed by inflation of a pneumatic thigh tourniquet at 300mm Hg and blood volume reduction measured by ^{99m}Tc -labeled erythrocytes. The methods were separated by twelve minutes deflation to regain equilibrium. The results

showed a reduction of blood volume from elevation at 45%, Esmarch at 64%, gauze at 62%, and Pomidor roll on cuff at 61%.

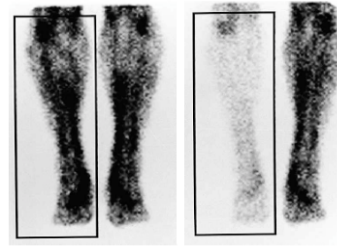


Figure 4: Blood volume reduction during exsanguination [4]

Using water displacement methods, Silver et al showed that a limb would swell immediately by approximately 10% of its original volume after release of a pneumatic tourniquet if exsanguinated beforehand [5]. He attributed this to hyperemia and edema in the post-operative state.

Limb protection before tourniquet application is common practice to prevent skin injury. Olivecrona et al in 2006 determined that an elastic stockinette under a pneumatic tourniquet cuff protected against the development of blisters during total knee arthroplasty better than cast padding or no padding [6]. The study consisted of ninety-two patients split into three groups: elastic stockinette, cast padding, no padding; blisters developed in zero, three, and seven patients, respectively. However, the study was limited in that they used contoured cuffs and straight cuffs at anesthesia discretion with 70-100mm Hg in contoured and 100-150 in straight cuffs. The duration was also longer in the group that developed blisters but not statistically significant.

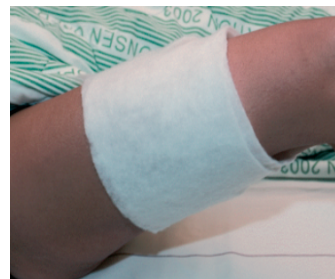

Figure 5: Limb Protection [6]

However, in a survey of 140 foot and ankle surgeons in 2006, only 16% use an elastic stockinette while most 66% use cast padding [7].

Standard of Practice

Although there is a wide variation in the exact method of hemostasis, tourniquet use and standards are arguably uniform across the nation. The ideal practice is one in which the lowest limb occlusion pressure is met while prevention of ischemic and pressure injury. Esmarch used as a tourniquet should be limited as pressures vary greatly and are often more than tourniquet pressure. Biehl et al showed this variation using 3" and 4" elastic Esmarch bandages with three to four wraps [8]. However, this study was limited on the low number of patients.

It is well studied that the widest cuff possible should be chosen. For a given limb circumference, a narrower cuff requires a much higher tourniquet pressure to stop blood flow. Wide bladders can occlude the blood flow with the use of a lower cuff pressure. Graham et al studied patients and found a logarithmic relationship between the limb occlusion pressure (LOP) and the ratio of cuff width to circumference [9]. Limb occlusion pressure, determined by doppler, can be defined as the "minimum pressure required, at a specific time in a specific tourniquet cuff applied to a specific patient's limb at a specific location, to stop the flow of arterial blood into the limb distal to the cuff" [10]. Optimum tourniquet pressure is determined by limb occlusion pressure plus a safety margin. McEwen et al performed a study that showed that the LOP needed reduced the average thigh tourniquet pressures by 19% to 42% as compared with the typical 300 to 350 mm Hg; the average pressure needed was 242 mm Hg in standard cuffs and 202 mm Hg in contoured cuffs. Final cuff pressure did not correlate to systolic pressure, which has been anecdotal. The Association of Peri-operative Registered Nurses recommend tourniquet pressure be set at limb occlusion pressure plus a safety margin. Their recommendations state a

safety margin of 40 mm Hg for LOP of <130 mm Hg, 60 mm Hg for LOP of 131-190 mm Hg, and 80 mm Hg for LOP of >190 mm Hg. Another way of determining limb occlusion pressure, compared to doppler, is via Graham's formula. This equation incorporates limb circumference, cuff width, and systolic and diastolic blood pressures. On a 2005 survey of foot and ankle surgeons, the vast majority based the cuff pressure exclusively on the limb size and systolic blood pressure [7].



Figure 6: Contoured Cuffs [10]

Furthermore, contoured cuffs occlude the flow of blood at lower pressures than straight cuffs that are of the same width. The cuff should overlap between three to six inches. If the overlap is more than six inches, rolling and wrinkling of the underlying skin and increased pressure in the area of the overlap may occur. In regard to the location of tourniquet placement, it should be based on location of procedure. The origin of muscle should not be overlooked. Also, thigh tourniquets are more painful and therefore require general anesthesia.

The consensus is that duration should not exceed two hours without a breathing period of ten to fifteen minutes. However, the Association of Peri-operative Registered Nurses recommends tourniquet duration to be limited to ninety minutes. Additional ischemic period should not exceed one hour without an additional breathing period.

Complications and Contraindications

Complications of tourniquet use are rare but an often-preventable occurrence in the operating room. One complication is tourniquet paralysis syndrome. Ochoa et al showed that most cases of nerve damage

were limited to the portion of the nerve beneath and near the edges of the cuff [11]. They showed that nerve injury is due to compressive neuropraxia rather than ischemic neuropathy. It was demonstrated that compression of the large myelinated fibers involves a displacement of the node of Ranvier from its usual position under the Schwann-cell junction

As previously discussed, post-tourniquet syndrome, is characterized by edema, stiffness, pallor, weakness without paralysis, and subjective numbness without objective anesthesia. It is found to be the result of an increased vascular permeability leading to interstitial and intracellular edema. Prolonged ischemia can cause local fiber necrosis and microvascular injury in the muscle.

Although very rare, venous thromboembolism is of concern due to the change in hematological effects after inflation. There is a hypercoagulable state after inflation secondary to hemostasis. Additionally, compartment syndrome is a complication in crush injuries and trauma in areas with a thin soft tissue envelope such as the ankle joint. Lastly, reperfusion syndrome occurs when long periods of tourniquet inflation go without breathing periods. Muscle ischemia leads to cellular hypoxia, tissue acidosis, accumulation of lactate, toxic metabolites, mediators, cytokines, and radicals. Muscle damage leads to CPK, myoglobin, and potassium increase. Simultaneous release of bilateral tourniquets may cause hypotension, metabolic acidosis, hyperkalemia, and arrhythmias. There have been case studies reviewing patients undergoing severe hypotension after release of bilateral tourniquets. The recommendation is to deflate thirty to forty-five minutes apart [12].

Contraindications to tourniquet use are not well defined in literature. The most common reason for lack of use is the duration and extent of procedure along with the patient's vascular status. Also, if the patient recently underwent vascular intervention, obtaining a bloodless field becomes less important as one does not want to compromise the intervention.

AV fistulas are less common in the thigh but have been seen; in these dialysis patients, tourniquets should be avoided. Recently diagnosed patients with deep venous thrombosis should avoid the use of tourniquets especially under treatment as to prevent emboli from occurring. Tourniquets should be avoided in infection and suspected malignancy as to not spread it any more proximally in the lower extremity. Lastly, sickle cell disease is a common contraindication; stasis, acidosis, and hypoxia all increase the chance for a sickle cell crisis. In these patients, it is important to know the frequency of sickle cell crises and whether the patient has the trait or the disease. One review observed twenty-one patients undergoing twenty-nine orthopedic operations with the SC gene and zero underwent complications [13].

Conclusion

In review, optimal exsanguination and limb protection helps prevent complications from occurring. Wide contoured cuffs have been shown to be ideal with lower pressures needed to gain limb occlusion pressures. The surgeon and staff should be aware of post-operative complications that occur directly as a result of tourniquet use, especially in patients with a complicated past medical history. Complications are few leading to lack of consensus but with optimal tourniquet hemostasis, most of the adverse events are preventable.

References

1. The Tourniquet Manual. Principles and Practice Smith, T.W.D Foot and Ankle Surgery, Volume 10 , Issue 1 , 53
2. Thompson, CJS (1942). The History and Evolution of Surgical Instruments. New York: Schuman's, p. 85

3. Savigny, JH (1798) from Welcome Library, London. A Collection of Engravings. The Most Modern and Approved Instruments Used in the Practice of Surgery. The Letter Press by T. Bensley.
4. Blond L, Kirketerp-Moller K, Sonne-Holm S *et al.* Exsanguination of lower limbs in healthy male subjects. *Acta Orthop Scand* 2002 ; 73 : 89-92.
5. Silver R, De La Garza J, Rang M, Koreska J. Limb swelling after release of a tourniquet. *Clin Orthop* 1986; 206:86-9.
6. Olivecrona C, Tidermark J, Hamberg P, Ponzer S, Cederfjall C. Skin protection underneath the pneumatic tourniquet during total knee arthroplasty: a randomized controlled trial of 92 patients. *Acta Orthop.* 2006;77:519-23.
7. Younger AS, Kalla TP, McEwen JA, Inkpen K. Survey of tourniquet use in orthopaedic foot and ankle surgery. *Foot Ankle Int.* 2005;26:208-217.
8. WC Biehl III, JM Morgan, FW Wagner Jr, RA Gabriel. The safety of the Esmarch tourniquet. *Foot Ankle*, 14 (1993), pp. 278–283.
9. Graham B, Breault MJ, McEwen JA, McGraw RW. Occlusion of arterial flow in the extremities at subsystolic pressures through the use of wide tourniquet cuffs. *Clin Orthop Relat Res.* 1993;286:257-61.
10. McEwen JA, Inkpen K, Younger A. Thigh tourniquet safety. *Surg Technol.* 2002;24:8-18.
11. Ochoa J, et al. "Nature of the nerve lesion caused by a pneumatic tourniquet". *Nature.* 233 (1971): 265-266.
12. O'Connor, Caroline, Murphy, Siobhan. *Journal of Perioperative Practice.* Date: August, 2007;17(8)
13. Stein RE, Urbaniak J: Use of the tourniquet during surgery in patients with sickle cell hemoglobinopathies. *Clin Orthop* 1980; 151:231–3